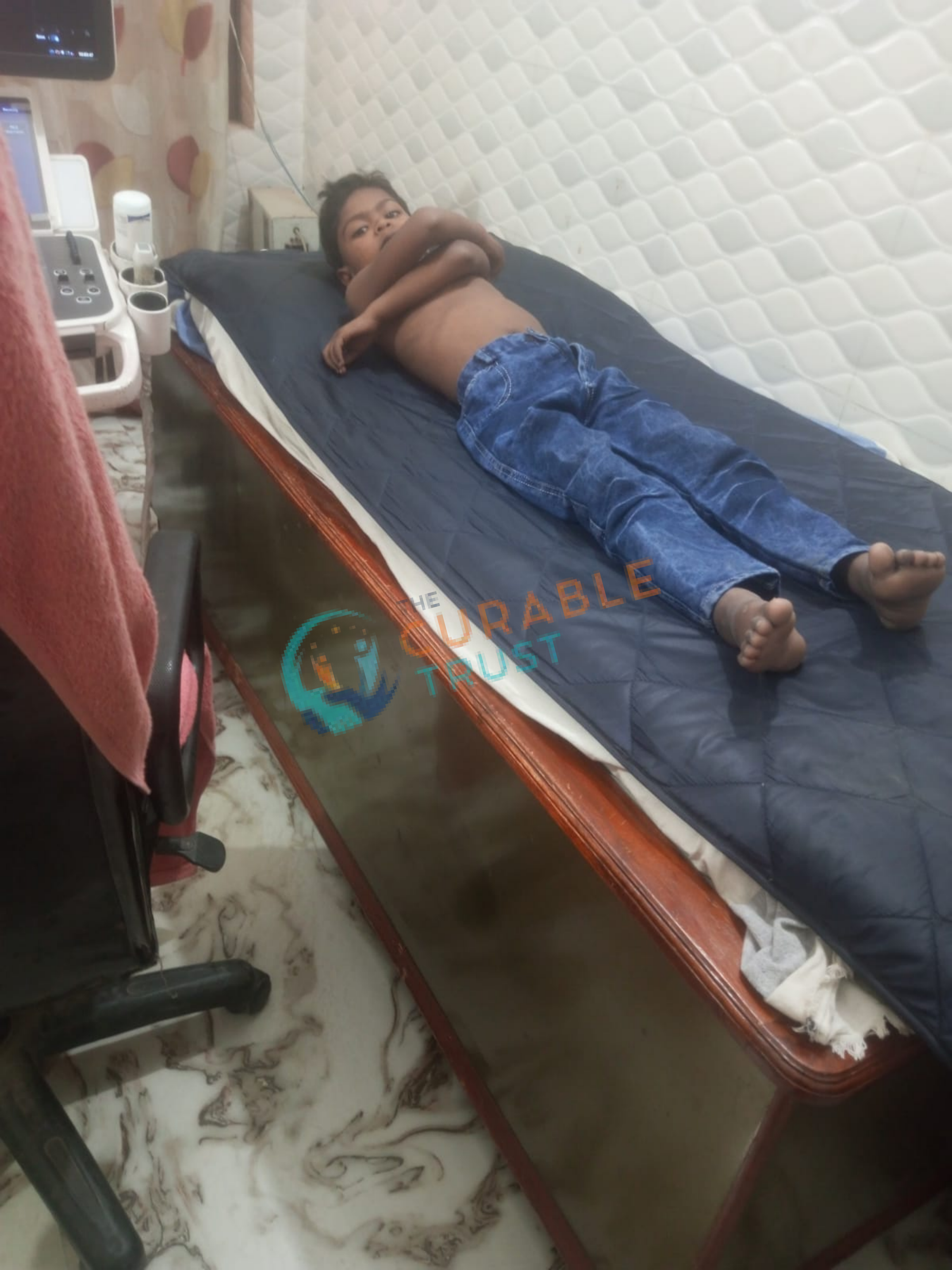



THE DURABLE TRUST

V 2026/014/0013540
 HID: 109104855
 Date 27/04/2026
 Name **SATYAM KUMAR**
 DO CHANCHAL PRASAD
 Phone No.
 Consultant Room 21

₹0
Cardiology
Paed. Cardiology
 7Y 5M / M
 General
 Dr. S
RAMAKRISHNAN
 DR ABHISHEK
 Prv. Reg. No.

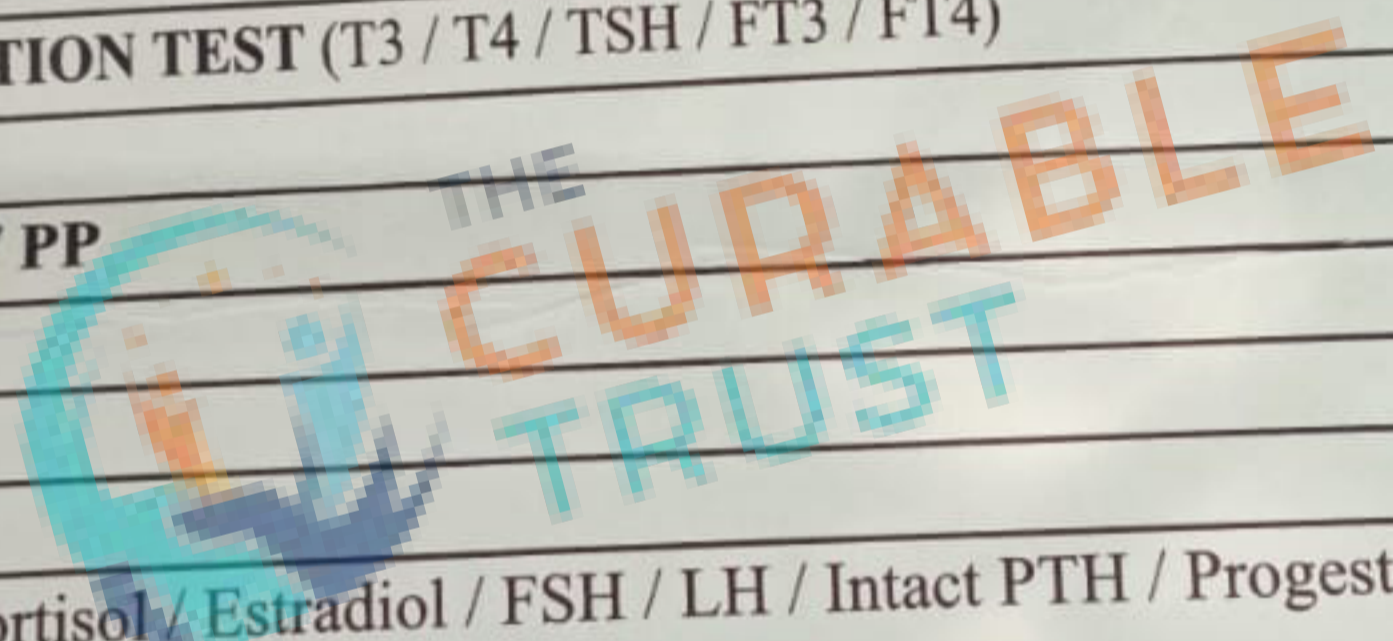
Centre
 L-26594866
 029
orm

24A

Date..... 27/04/26

Paste
 Patients Details:
 UHID:

S.NO.	(Tick the entire panel or encircle the required tests in the panel)
1	CBC / ESR
2	LFT (Total Bilirubin / Direct / Indirect / SGOT (AST) / SGPT (ALT) / Alkaline Phosphates (ALP) / Albumin / Globulin / Total Protein / Albumin - Globulin ratio)
3	KFT (Urea / Creatinine / Sodium / Potassium / Uric Acid / Chloride)
4	LIPID PROFILE (Total Cholesterol / LDL - Cholesterol / HDL - Cholesterol / VLDL Cholesterol / Triglycerides / LDL - HDL Ratio)
5	THYROID FUNCTION TEST (T3 / T4 / TSH / FT3 / FT4)
6	HbA1c
7	Glucose Fasting / PP
8	CRP
9	ASO
10	Viral Markers
11	HORMONES (Cortisol / Estradiol / FSH / LH / Intact PTH / Progesterone / Prolactin / Testosterone)
12	VITAMINS (Vitamin D3 / Vitamin B12 / Serum folate)
13	DRUGS (Carbamazepine / Valproic acid / digoxin, cyclosporine, tacrolimus / everolimus / Phenytoin (Eptoin))
14	IRON STUDY PANEL (Iron / TIBC / Transferrin / Ferritin / % Saturation)
15	Prothrombin Time / INR / APTT
16	Coagulation Factors (D-Dimer / ATIII, Protein C, Protein S, Factor V Leiden)
17	Homocysteine
18	Cardiac Markers (NT proBNP / CK / CK-MB / Troponin T / Myoglobin)
19	Catecholamines : Plasma / 24-hour Urine
20	MISCELLANEOUS TEST: Fibrinogen / Total PSA / RA Factor / AFP / NMOSD / MOG / Procalcitonin / Total Amylase / Autoimmune Encephalitis Panel
21	Any other test (Please mention the name) :



Consultant Signature.....

हृदय वक्ष एवं तंत्रिका विज्ञान केन्द्र
 ब० रो० वि०
 अ० भा० आ० सं०, नई दिल्ली-110029
 Cardiothoracic & Neurosciences Centre, O.P.D.
 A.I.I.M.S., New Delhi-110029

दिनांक/Date

विभाग
 Deptt.

यू०एच०आई०डी०सं०
 UHID No.

CV 2026/014/0013540

UHID: 109104855

Date 27/04/2026

MON

Name SATYAM KUMAR

S/O CHANCHAL PRASAD

Phone No.

Consultant Room 21

SR Room 14



२०

Cardiology
 Paed. Cardiology

7Y 5M /M

General

Dr. S
 RAMAKRISHNAN
 DR ABHISHEK

Prv. Reg. No.

Diagnosis

27/4/26 ACHD / 70% / large pm vsd / mod. A2

ASW

1) 70% Lasix 10mg po B3

2) 70% Aldactone 25mg 1/2 - 1/2

3) 50% vit cotol 5ml po OD
 (5ml / 32-97)

4) ELW reports in OPD

27

4:30

SpO2 - 100%

HR - 85

ECG

- NSR

- HR - 96/m

- NAD

- LVH / LVVO +

Left aortic arch with normal branching pattern, No CoA / PDA,
Normal systemic & pulmonary venous connection, No LSVC,
Good biventricular contractility.

Final Diagnosis:

Originally Large PM - VSD(11.7x9mm on LV side) with outlet extension (effective size -5mm) significantly restricted by RCC, NCC commissural prolapse with significant RCC buckling with Lt. to Rt. shunt with gdt of 48mmHg
RV cavity muscle bundle with gdt of 21mmHg,
Dilated LA/LV, Moderate AR with eccentric jet, AR VC - 0.34

Child Heart Care Team Decision:


Family counselled about Very complex CHD & Delayed presentation.
Needs early VSD closure + Ao valve Repair/Replacement + DCRV Repair.
Refer to surgical team.


Note:

CXR:- CTr - 0.5, LV apex, Increased PBF.

Prescription Notes:

Tab. Lasix(40mg) 10mg BD
Tab. Spironolactone(25mg) 12.5mg BD


Dr. Yogesh C Sathe
Pediatric Cardiologist



Dr. Prashant Thakur
Pediatric Cardiologist

Dr. Deendayal Nagar
Pediatric Cardiologist

→ Cardiology ETC का सिर्फ
↓
CIVS

All Medical Services viz, OPD, Investigations, Admission, Surgeries, Interventions, including food are provided TOTALLY FREE OF COST. There are no charges / fee of any kind levied on the patients at

हृदय वक्ष एवं तंत्रिका विज्ञान केन्द्र
CARDIO-THORACIC & NEURO-SCIENCES CENTRE

(42)

अखिल भारतीय आयुर्विज्ञान संस्थान

A. I. I. M. S. Hos

नाम

Name

एक्स-रे नम्बर

X-Ray No.

हस्पताल यू.एच.आई.डी

Hosp. UHID No.

एक्सरे जांच के लिए अ

Examination Required

चिकित्सक की जांच रिपोर्ट :

Clinical Information :

CV 2026/0013540

UHID: 109104855

Date 27/04/2025

Name SATYAM KUMAR

S/O CHANCHAL PRASAD

Phone Non/CI

Consultant Room 21

SR Room 14

MON

Cardiology

Paed. Cardiology

TY SM IM

General

Dr. S

RAMAKRISHNAN

DR ABHISHEK

Prv. Reg. No.

एक्सरे-फार्म

REQUISITION FORM

लिंग

Sex

आय

Income

विभाग

Unit

Ambulatory/Non



CXR PA

[Handwritten Signature]

चिकित्सक के हस्ताक्षर

SIGNATURE OF MEDICAL OFFICER

रेडियोग्राफर के लिए

FOR RADIOGRAPHERS USE

किसी दवा का बुरा प्रभाव

Any History of Allergy

अन्तिम माहवारी तिथि

LMP

कोई पुराने एक्स-रे

Any Previous X-Rays

पहचान चिन्ह
Identification Mark

अंगूठा निशान
Thumb Impression

कमरा नं. Room No.	फिल्म साइज Size & No. of Films	के. वी. KV	एम.ए.एस. MAS
हस्ताक्षर / Signature			

रिपोर्ट
REPORT

एक्स रे-चिकित्सक
RADIOLOGIST



NEHRU HOSPITAL BRD MEDICAL COLLEGE
GORAKHPUR
UTTAR PRADESH



ABHA Address : 91202845417858@abdm/ Abha No : 91-2028-4541-7858
पंजीकरण संख्या (Registration No (UHID)) : 20260108067
टोकन संख्या (Token No) : 31
कमरा संख्या (Room No) : SEPARATE BUILDING, 500 BEDS HOSPITAL, Ground, Room - 16
Doctor Days : MONDAY

Pediatrics OPD

नाम (Name) : Mr. Satyam Kumar
उम्र/ लिंग (Age/Sex) : 6Y / M
विभाग (Department) : Paediatrics
विभाग पंजीकरण संख्या (Dept. Reg. No) : 20260007731
डॉक्टर : Dr Bhoopendra Sharma Dr Vikas Agrawal Dr Aaveen
रोगी का प्रकार (Patient Type) : General
संरक्षक का नाम (Guardian Name) :

पंजीकरण राशि (Registration Amount) : Rs. 1
मोबाइल नंबर (Mobile No) : *****445
पता (Address) : RO THAWI TOLA PS PATHERWA, KUSHI NAGAR (UTTAR PRADESH)
पंजीकरण की तिथि (Date of Registration) : 06/04/2026 12.36 PM


ओ पी डी नं-16
बाल रोग विभाग
यूनिट-A-सोमवार

MLC Patient : NO

वजन - 15.6 Kg
- 11719
Review in Pediatric - OPD

Δ - VSD ?

Refer to CARDIOLOGY
Behan (17kg)



THE CURABLE TRUST

Referred to higher centre for further workup and management
(Plimbo UKW, SGP GI UKW)
(Rm L UKW, Pediatric Cardiology)

HR - 102/min
SpO2 - 94%
RR - 24/min
BP - 104/64 mmHg


Aedw
2D echo

Moderate size (7.0mm) SUB-AORTIC VSD
L to R shunt > 2:1
mild AR
Normal LV systolic function

यह पर्चा 15 दिनों के लिए मान्य है।

Dr. Mr. Ashutosh Kumar Singh

Date Time: 06/04/2026 12.36 PM



हृदय वक्ष एवं तंत्रिका विज्ञान केन्द्र
CARDIOTHORACIC & NEUROSCIENCES CENTRE
 अखिल भारतीय आयुर्विज्ञान संस्थान, नई दिल्ली-११००२६
 A.I.I.M.S., New Delhi-110026

62

विशेष जांच पड़त
Requisition for

दिनांक
 Date

नाम
 Name

क्लिनिक डायगनासि
 Clinical Diagnosis

दवाईयाँ
 Drugs

जांच पड़ताल की माँग
 Investigations requested

इको
 STI/Echo / Vector / Redionucleiude Study / Others

CV 2026/014/0013540
 UHID: 109104855
 Date 27/04/2026 MON
 Name **SATYAM KUMAR**
 S/O CHANCHAL PRASAD
 Consultant 21 SR Room 14
 Address: THAVAI TALA KASHI NAGAR, UTTAR PRADESH INDIA
 7Y 5M /M
 Cardiology
 Paed.Cardiology
 THE CLIPTRABLE TRUST

ECHO on wednesday

10:00 AM (L → R)

Dr. Lalita/LA
 mod. A/O

C
 U
 D
 N
 S/क्ष
 C/ard
 A

बिस्तर
 Bed

विचारार्थ
 Ref. by

@ 2PM -
 29/4/26

हस्ताक्षर परामर्शदाता
 Signature of Consultant

डा. अतुल कुमार शाही

DR. ATUL KUMAR SHAHI

M.D. (Medicine), D.M. (Cardiology)

P.G.I. Chandigarh

हृदय रोग विशेषज्ञ

Reg. No. 33939 (MCI-UP)



पेस

हार्ट सेन्टर प्रा. लि.

D-101, बुद्ध विहार कामर्शियल, तारामण्डल, पैडलेगंज से रुस्तमपुर हाईवे पर, गोरखपुर. मोबाईल : 7668006926, 9695889878

Pt's Name : Mr. Satyam Kumar Residence : Bandila Age/Sex : 45 M Date : 16 MAR 2026

Illness : 7mm Substernal MILD AR ECG : EF+ (2) PR : BP : JVP : Pall / cya / clubbing / Ped. Oed. / Jaundice

CART : CVS : Respiratory :

PCI : ABD : CNS :



TEMP :

Ad. Surg.

Ti Amifm 40/4 2026

AIMS MD
Cardiology

By a line





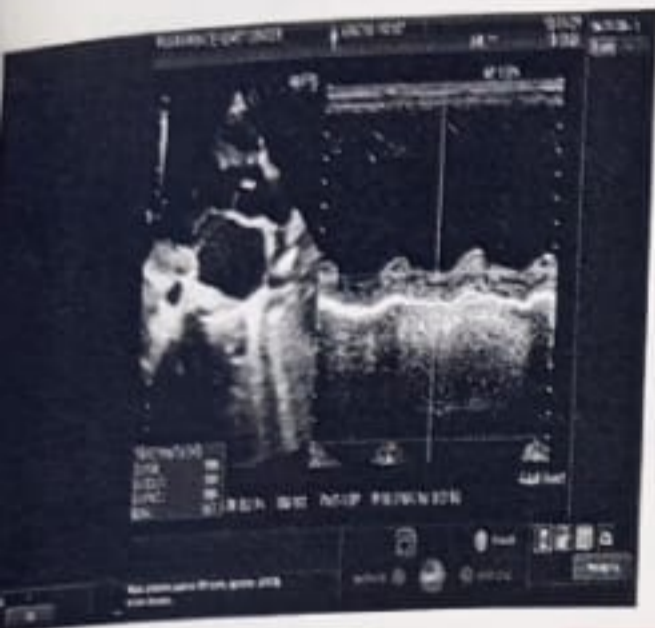
Name :: MASTER SATYAM

Sex/Age :: Male/8 Years

Patient ID :: 16Mar2026_024

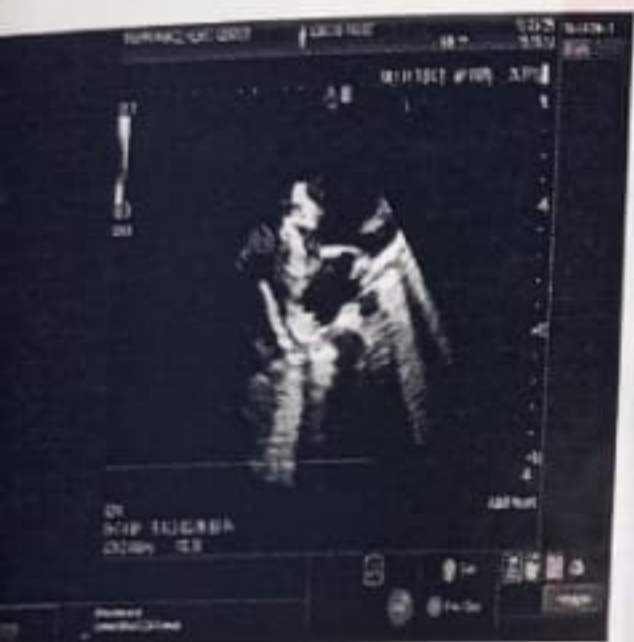Procedure ::
ECHOCARDIOGRAPHY

Date :: Mar 16, 2026



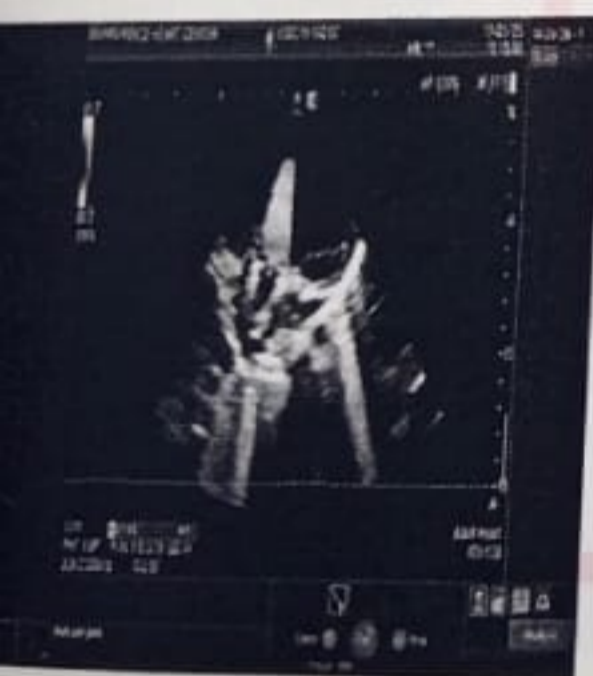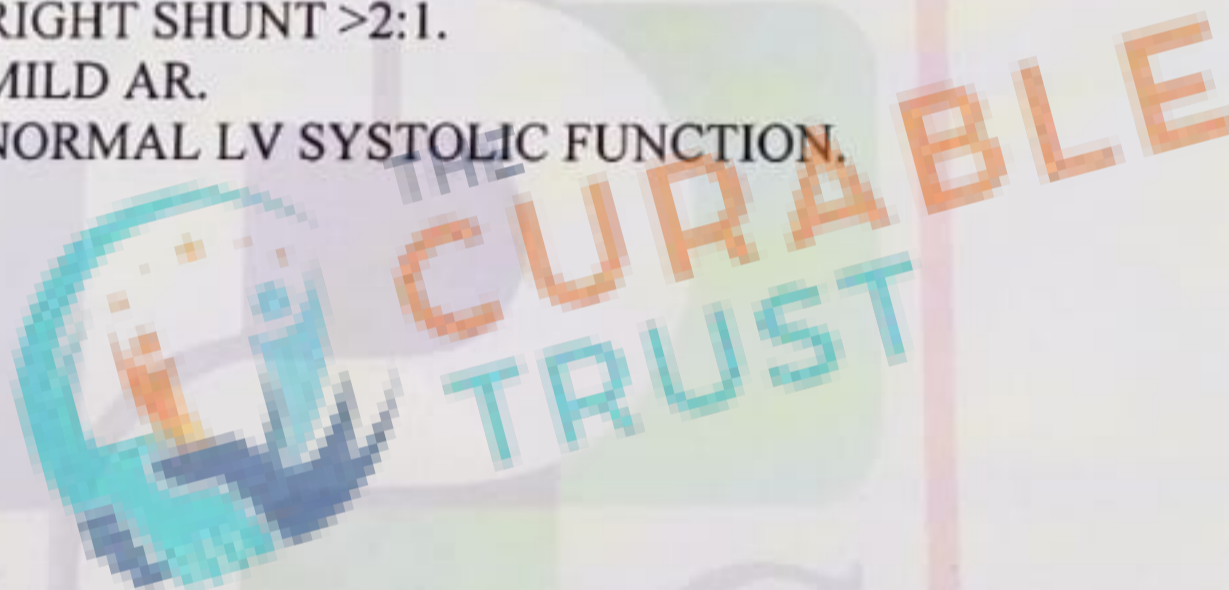
SPECIAL COMMENT :-

- NO CLOT/VEGETATION/PERICARDIAL EFUSSION/RWMA.
- SITUS SOLITUS. BASE TO APEX LEFT.
- AV & VA CONCORDANT.
- IVC TO RA & 3PV TO LA.
- GREAT ARTERIAL RELATIONS NORMAL.
- NO ASD/ PDA/ CoA.
- MODERATE SIZE [7.0mm] SUB - AORTIC VSD WITH LEFT TO RIGHT SHUNT >2:1.



FINAL IMPRESSION :-

- MODERATE SIZE [7.0mm] SUB - AORTIC VSD WITH LEFT TO RIGHT SHUNT >2:1.
- MILD AR.
- NORMAL LV SYSTOLIC FUNCTION.



S AVAILABLE

ography

est

DR. ATUL KR. SHAHI M.D. D.M.

- ◆ Temporary Pacemaker
- ◆ Private Room
- ◆ Permanent Pacemaker
- ◆ Angiography



PACE

HEART CENTRE PVT. LTD.

D-101, Budh Vihar Commercial, Taramandal,
 Paidaleyganj to Rustampur Highway, Gorakhpur (U.P.)
 Mobile : 7668006926, 9695889878
 Timing : 10.00 am to 6.00 pm
 Sunday Closed

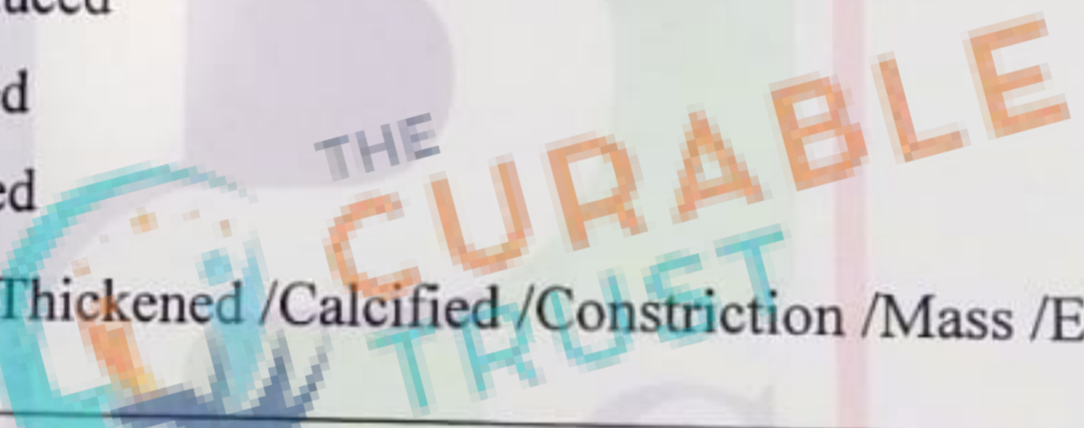PATIENT ECHO WINDOW :- POOR / ADEQUATE / GOOD

M-MODE MEASUREMENTS :-

AORTA:.....36.....mm; LEFT ATRIUM:.....35.....mm
 RVIDd :.....mm
 IVSd :7.....mm ; IVSs :.....11.mm
 LVIDd :64.....mm ; LVIDs:..45.....mm
 LVPWd : ...7.....mm ; LVPWs:..12.....mm
 EPSS :mm
 LV MASS :.....
 IVS/LVPW RATIO :.....
 FS :.....25.0% ; LVEF :.....52.0..%
 EDV : ; ESV :
 IVS : NORMAL / SIGMOID / PARADOXICAL
 IVS : VSD
 IAS : INTACT

CARDIAC CHAMBERS :-

LEFT VENTRICLE :- Normal / Hypertrophy / Dilated / Thinned out / Aneurysmal
 FUNCTION :- Normal / Reduced
 RIGHT VENTRICLE :- Normal/Hypertrophy/Dilated/Apical Obliteration/Rudimentary
 FUNCTION :- Normal / Reduced
 LEFT ATRIUM :- Normal / Enlarged
 RIGHT ATRIUM :- Normal / Enlarged
 PERICARDIUM :- Normal / Absent / Thickened / Calcified / Constriction / Mass / Effusion
 V. VOLUME & EF :-



M-MODE :-	MOD. SIMPSON :-
ESV :ml/m2	ESV :ml/m2
EDV :ml/m2	EDV :ml/m2
EF :55.0%	EF :%

MITRAL VALVE STUDY :-

ANTERIOR MITRAL LEAFTLET :- Normal/Thickened/Doming/Calcified/Prolapse /Flail/SAM/Cleft/Perforation/Restricted Mobility	
POSTERIOR MITRAL LEAFLET :- Normal/Thickened/Doming/Calcified/Prolapse /Flail/SAM/Flat/Fixed/Cleft/Perforation/Restricted Mobility/Paradoxical	
MITRAL VALVE SCORE :- Thickness :-	Mobility :-
Subvalvular.Apparatus :-	Calcification :-
Total :-	
MITRAL STENOSIS :- Absent / Mild / Moderate / Severe	
MVA:.....cm2;cm2 (By 2D), (By PHT)	
Max. Gradient :.....mm Hg ;MDG :.....mm Hg ;HR :...../min.	

AVAILABLE

- graph
- graphy and Colour Doppler
- ardiography
- ageal Echocardiography
- ◆ Temporary Pacemaker
- ◆ Permanent Pacemaker
- ◆ Coronary Care Unit
- ◆ Private Room
- ◆ Angiography
- ◆ Angioplasty



ECHOCARDIOGRAPHY REPORT

106

DEPARTMENT OF CARDIOLOGY, CARDIOTHORACIC CENTRE
ALL INDIA INSTITUTE OF MEDICAL SCIENCES, NEW DELHI-110029

NAME: Satyam Kumar AGE: 7y SEX: M DATE: 29/4/2026
ECHO NO: 1109104855 CV NO: UHID NO: C.R. No:
HEIGHT: cm WEIGHT: Kg. BSA: m² ref. Physician: P.K

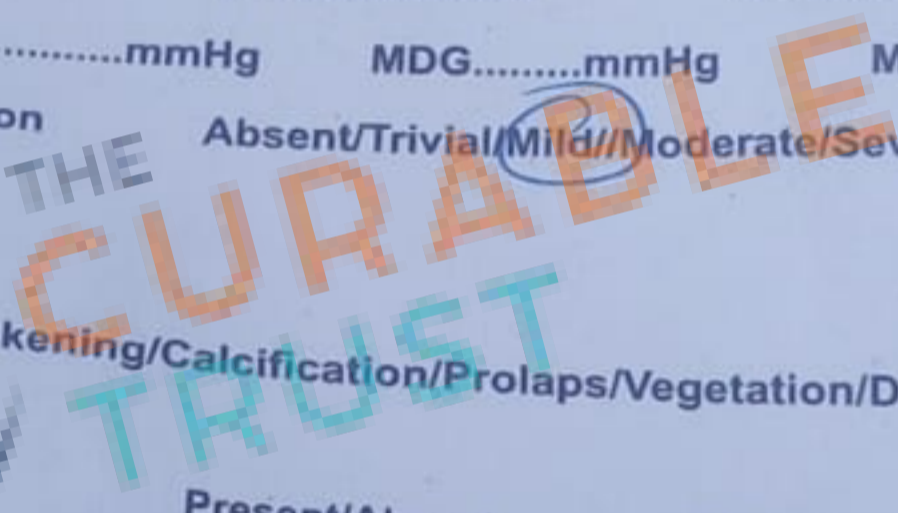
Referring Diagnosis:
Quality of Imaging: Poor/Adequate/Good Done by Dr. Abhishek Checked by Dr.

MITRAL VALVE
Morphology: AML-Normal/Thickening/Calcification/Flutter/Vegetation/Prolapse/SAM/Doming
PML Normal/Thickening/Calcification/Prolapse/Paradoxical motion/Fixed.
Doppler: Subvalvular deformity present/Absent Score:
Normal/Abnormal
Mitral stenosis: Present/Absent RR Interval: msec
EDG: mmHg MDG: mmHg MVA: cm²
Mitral regurgitation: Absent/Trivial/Mild/Moderate/Severe

TRICUSPID VALVE
Morphology: Normal/Atresia/Thickening/Calcification/Prolaps/Vegetation/Doming
Doppler: Normal/Abnormal
Tricuspid stenosis
Present/Absent RR Interval: msec
EDG: mmHg MDG: mmHg
Tricuspid regurgitation: Absent/Trivial/Mild/Moderate/Severe Fragmented Signals
Velocity: m/sec Pred. RSVP-RAP+: mmHg

PULMONARY VALVE
Morphology: Normal/Atresia/Thickening/Doming/Vegetation
Doppler: Normal/Abnormal
Pulmonary stenosis: Present/Absent Level:
Pulmonary Regurgitation: PSG: mmHg
Present/Absent Pulmonary annulus: mm
Early diagnostic gradient: mmHg
End Diastolic gradient: mmHg

AORTIC VALVE
Morphology: Normal/Thickening/Calcification/Restricted opening/Flutter/Vegetation
Doppler: Normal/Abnormal No. of cusps: 1/2/3/4
Aortic stenosis: Present/Absent Level:
PSG: mmHg Aortic annulus: mm
Aortic regurgitation: Absent/Trivial/Mild/Moderate/Severe



D-101, बुद्ध विहार कामर्शियल, तारामण्डल, पैडलगाज ए फरतमपुर हाइवे पर 11113 3
Mobile : 7668006926 9605900070
(य.पी